

Bull terrier hereditary nephritis: A model for autosomal dominant Alport syndrome

JENNIFER C. HOOD, JUDY SAVIGE, ANNE HENDTLASS, MARY M. KLEPPEL, CLIVE R. HUXTABLE,
and WAYNE F. ROBINSON

*Section of Pathology, School of Veterinary Studies, Murdoch University, Perth, Western Australia, and *University Department of Medicine, Austin Hospital, Melbourne, Victoria, Australia; and Department of Pediatrics, University of Minnesota, Minneapolis, Minnesota, USA*

Bull terrier hereditary nephritis: A model for autosomal dominant Alport syndrome. Bull terrier hereditary nephritis is inherited as an autosomal dominant disease and causes renal failure at variable ages in affected dogs. The aims of this study were to compare the clinical, ultrastructural and immunohistochemical features of bull terrier hereditary nephritis with the characteristics of the human forms of Alport syndrome. Many animals with bull terrier hereditary nephritis have hematuria, and some have anterior lenticonus. However, deafness is not associated with the renal disease, and affected dogs do not have the large platelets that are occasionally seen in patients with autosomal Alport syndrome. The glomerular capillary basement membrane (GCBM) in affected bull terriers has an identical ultrastructural appearance to that seen in X-linked Alport syndrome, with lamellations and intramembranous electron-dense deposits. However, both the Goodpasture and the Alport antigens, which represent parts of the alpha 3(IV) and alpha 5(IV) collagen chains, respectively, are present in the GCBM of affected dogs. Bull terrier hereditary nephritis represents an animal model for autosomal dominant Alport syndrome, and can be used to further examine how genetic mutations affect a basement membrane protein and the corresponding membrane structure.

The diagnosis in humans of X-linked Alport syndrome is suspected on a positive family history and the demonstration of hematuria, together with deteriorating renal function, a high-tone sensorineural deafness, anterior lenticonus, and a retinopathy in the more severely affected [1, 2]. The diagnosis is confirmed with the appearance of a lamellated glomerular capillary basement membrane (GCBM), often with intramembranous electron-dense deposits [3, 4], and sometimes by the absence of the Goodpasture antigen [5, 6], which is part of the non-collagenous domain of the alpha 3(IV) collagen chain [7, 8]. All mutations recognized to date in patients with X-linked Alport syndrome have involved the gene for the alpha 5(IV) chain of type IV collagen [2, 9, 10], and the abnormal alpha 5(IV) chain probably reduces the stability of the alpha 3(IV) chain and causes the disappearance of the Goodpasture antigen.

About one in six patients with Alport syndrome has an autosomal recessive form [2], where hearing loss and eye abnormalities may be less common [2, 11]. This phenotype includes low platelet

counts, large platelets, abnormal platelet aggregation to some agonists [12, 13], and occasionally leukocyte inclusions [14]. Mutations have been demonstrated in the gene for the alpha 3(IV) and alpha 4(IV) collagen chains in several families with autosomal recessive disease [15].

Samoyed hereditary glomerulopathy represents an animal model for X-linked Alport syndrome [16–22]. Affected males develop hematuria and proteinuria, and die of renal failure by one year of age [17], but these dogs do not have hearing or eye abnormalities. The GCBM of affected males is lamellated [18, 19] and the Goodpasture antigen is absent [20, 21]. Carrier females usually have mild disease: there is focal splitting of the GCBM that does not progress with time, and the Goodpasture antigen is present [22]. The Samoyed model has been used to show that dietary protein restriction can delay the onset, and reduce the severity of renal damage in an inherited glomerulopathy [23].

Bull terrier hereditary nephritis is another inherited renal disease [24, 25], but it is inherited as an autosomal dominant condition [26], unlike most cases of Alport syndrome and Samoyed hereditary glomerulopathy. Evidence for an autosomal dominant inheritance includes the demonstration of at least one affected parent for each diseased offspring, the approximately equal numbers of affected males and females, and the occurrence of nephritis in each generation [26]. Diseased bull terriers present from early life through to late adulthood with signs of renal failure [24, 25]. Proteinuria can be demonstrated in all affected animals, and an elevated urinary protein creatinine ratio (UPC) is a consistent indicator of subclinical disease [27]. The rate of progression to renal failure varies, with death occurring at ages ranging from a few months to 10 years.

Light microscopic examination of kidneys from uremic dogs shows extensive nephron loss [28] (Fig. 1). The remaining glomeruli may have atrophic tufts, and marked cystic dilatation of Bowman's capsule occurs. Glomerular fibrosis is a variable feature and is not usually associated with the cystic glomeruli. Sclerotic obsolescent glomeruli and fetal-like glomeruli are often found, and periglomerular fibrosis is common. Other characteristic findings include intense radial fibrosis especially at the corticomedullary junction, prominent tubular dilation, and interstitial foci of inflammatory cells [28].

The aims of this study were to compare the clinical, ultrastructural and immunohistochemical features of bull terrier hereditary

nephritis, with X-linked and autosomal Alport syndrome and Samoyed hereditary glomerulopathy.

Methods

Dogs

Affected adult bull terriers. UPC was estimated on a random voided urine specimen using a Cobas Mira autoanalyzer (Hoffman-LaRoche) and confirmed on a second specimen taken at least one month later. Renal tissue was obtained by biopsy or immediately after death, 3 to 4 μm sections were cut and stained with Hematoxylin and Eosin.

All affected animals had a UPC greater than 0.3 [26], and some had in addition laboratory evidence of renal failure or the characteristic light microscopic appearance of this condition.

Normal dogs. These were breeds other than bull terriers that had a UPC less than 0.3, usually on two occasions one month apart. There was no laboratory evidence of renal failure, and where examined, there was a normal light microscopic appearance of kidney sections.

Clinical features

Hearing. The external ears were examined and quantitative audiometry was performed using brainstem auditory-evoked responses in five affected bull terriers, four unaffected bull terriers and four normal dogs. Responses to high intensity clicks [and in some cases mid (10 kHz) to high frequency (20 to 30 kHz) frequency-pure tone bursts] were measured in each ear using subcutaneous electrodes. Signals were averaged by a Medelac averager using either 512 or 1024 sweeps, and recorded directly on lineographic print paper. All tests were repeated unless a clear positive response was observed.

Eyes. The eyes of three affected bull terriers were dilated with topical 1.0% tropicamide (Mydracyl) and examined by direct and indirect ophthalmoscopy, and slit-lamp biomicroscopy, by an ophthalmologist who had experience with examining the eyes of patients with Alport syndrome, assisted by a veterinary ophthalmologist.

Platelet size. Platelet size was assessed on examination of peripheral blood films from 37 affected bull terriers and 10 normal dogs. The areas of 50 randomly selected platelets from each animal were measured using the MacIntosh IMAGE program. The areas of the platelets from affected and unaffected animals were then compared using the Student's *t*-test.

Urinalysis. One hundred and ninety-six voided urine specimens were collected from 122 normal and affected bull terriers (48 males and 74 females). No specimen was collected within 48 hours of catheterization nor from any animal in estrus. Hematuria was present if the urines were positive for blood on testing with Multistix (Ames Co.), or any red cells were observed in a field by light microscopy at a magnification of $\times 600$.

Any association of hematuria with proteinuria was determined, using the Instat Instant Biostatistics Software Program (Graph Pad Software).

Immunofluorescent, ultrastructural and immunohistochemical examination of the kidneys

Direct immunofluorescent examination of the kidneys. Kidney tissue from eight affected Bull terriers was collected into 10% buffered formalin. Three to 4 μm paraffin-embedded sections

were cut, the paraffin removed with xylene and alcohol washes, and the sections digested with 0.1% protease (Sigma) in 0.01 M PBS, pH 7.6 at 37°C for 30 minutes, and washed with PBS. These were then incubated with 1/40 rabbit anti-dog IgG (Cappel Research Products) in PBS, at room temperature for 30 minutes, before washing and applying a 1/40 dilution of fluorescein-conjugated goat anti-rabbit IgG (Cappel Research Products) in PBS at 4°C for 30 minutes. Slides were then mounted in buffered glycerol and fluorescence was graded 0 to 3+ by two independent observers using an epifluorescence microscope (Olympus).

Ultrastructural examination of the kidneys. Kidney tissue was obtained at post-mortem, fixed in 1.5% chilled glutaraldehyde in 0.1 M PBS, post-fixed in 1% Dalton's osmium tetroxide and embedded in Epon 812 (TAAB Laboratories).

Thin sections were cut on a Reichert Ultra Cut E microtome, supported on 200 mesh copper grids, and then stained with saturated uranyl acetate and lead citrate. After carbon coating, the grids were examined in a Philips 301 transmission electron microscope.

Qualitative examination of Goodpasture and Alport antigens. Kidney tissues from four affected bull terriers, one normal bull terrier and three normal dogs were obtained immediately after death. These were embedded in Tissue-Tek OCT (Miles), snap-frozen in liquid nitrogen and 3 μm sections cut, air-dried and fixed in 95% ethanol for five minutes. Sections were then incubated with undiluted Mab A2 [29], a mouse monoclonal antibody directed against the Goodpasture antigen, at 4°C for one hour. Other sections were denatured with 0.1 M glycine 6 M urea [30], pH 3.5 for one hour at 4°C, washed with PBS and then incubated with undiluted Mab A7 (specific for the Alport antigen, [29]) at 4°C for one hour.

Slides were then washed in PBS, and incubated with 1/50 affinity-isolated fluorescein conjugated sheep F(ab')₂ anti-mouse IgG (Silenus), and examined using an Olympus epifluorescence microscope. Fluorescence was graded 0 to 3+ by two independent observers.

Quantitation of Goodpasture antigen using an ELISA

Preparation of GCBM. GBM was prepared from one affected bull terrier and one unaffected dog. Glomeruli were obtained by differential sieving as previously described [31]. Briefly, portions of renal cortex were pushed through 150 μm and 250 μm sieves, before collecting the isolated glomeruli on a 75 μm sieve. The glomeruli were washed three times, and sonicated at 18 μm in 30 second bursts until they were disrupted on examination by light microscopy. The GCBM was then digested with collagenase type I (Sigma type I), and the collagenase inactivated by heating to 60°C for five minutes.

Quantitation of the Goodpasture antigen. The collagenase digest was coated to microtitre plates at 37°C for one hour using 1/1000, 1/400, 1/200 and 1/100 dilutions of a starting concentration of 0.7 $\mu\text{g}/\text{ml}$. The wells were washed, incubated with a 1/125 dilution of serum from a patient with Goodpasture's syndrome, washed with PBS, and then incubated with 1/1000 dilution of alkaline phosphatase-conjugated goat anti-human IgG (Silenus). The color was developed with para-nitrophenylphosphate (Sigma) and the optical density determined at 405 nm (Titretek Multiscan Plus).

Fig. 1. A. Light microscopic appearance of post-mortem kidney from a dog aged 10 years with hematuria, proteinuria and azotemia (Jones Silver stain, $\times 200$). This shows cystic dilatation of Bowman's capsular space, thickening of the capsule itself, atrophic glomeruli and some sclerotic glomeruli. **B.** Light microscopic appearance of kidney biopsy from dog aged 7 years with hematuria and proteinuria (hematoxylin and eosin, $\times 400$). This shows mesangial proliferation, with thickened capillary loops, mildly thickened Bowman's capsule (larger glomerulus) and a fetal-like glomerulus.

Table 1. High frequency hearing loss in bull terrier hereditary nephritis

Animals	Left ear	Right ear
Proteinuric bull terriers	normal	normal
	normal	slight loss
	marked loss	slight loss
	marked loss	marked loss
	marked loss	marked loss
Non-proteinuric bull terriers	normal	normal
	normal	slight loss
	slight loss	marked loss
	marked loss	marked loss
Unaffected dogs (non-bull terriers)	normal	normal
	normal	normal
	normal	normal
	normal	normal

Table 2. Number of bull terriers assessed for high frequency hearing in different age groups

Age years	Deaf	Slightly deaf	Not deaf
1 to 3	2	0	0
4 to 6	2	1	1
7 to 9	1	1	1

Results

Clinical features

Hearing. No dog was profoundly deaf as assessed by the absence of a click response. Seven affected bull terriers showed mid-to-high frequency hearing deficits (Table 1), but deafness was also observed in unaffected bull terriers. None of the other breeds showed this hearing loss. Median age of the bull terriers (4.8 years) was higher than that of the non-bull terriers (3.0 years) but no age related trend was found among the bull terriers (Table 2). The youngest two bull terriers had marked deafness but did not have proteinuria.

Eyes. Affected dogs had the changes of anterior lenticonus seen also in human Alport syndrome.

Platelets. When the platelet sizes of affected and unaffected bull terriers were compared, the platelets from affected dogs were significantly larger ($P = 0.0023$). However, this did not take into account the large number of platelets examined to find a very small difference in platelet size. In addition, a linear discrimination analysis was performed to determine the extent to which log of platelet area could discriminate between the two groups. Discrimination was poor (0.608 for log of platelet area of affected dogs compared with 0.580 for log of platelet area of unaffected animals). These results showed that the proportion of animals that would be correctly classified into affected and unaffected dogs on the basis of platelet area would be 53%.

Urinalysis. Urine from 65 samples (33%) contained blood, and 38 of these also demonstrated proteinuria (Table 3). The odds ratio was calculated to be 2.0059, with a 95% confidence interval of 1.0972 to 3.6707 (using the approximation of Woolf). Bull terriers with proteinuria were more than twice as likely to have some degree of hematuria as non-proteinuric bull terriers.

Table 3. Hematuria in bull terrier hereditary nephritis

	Number of dogs		
	Hematuric	Non-hematuric	Total
Proteinuric	38 (19%)	54 (28%)	92 (47%)
Non-proteinuric	27 (14%)	77 (39%)	104 (53%)
Total	65 (33%)	131 (67%)	196 (100%)

Immunofluorescent, ultrastructural and immunohistochemical examination of the kidneys

Direct immunofluorescent examination of the kidneys. There were no immunoglobulin deposits in the GCBM, the mesangium, nor in the tubules of any of the kidneys from affected dogs.

Ultrastructural examination of the kidneys. The GCBM from affected dogs was thickened, lamellated and vacuolated with some subepithelial frilling, and occasionally electron dense deposits were present between the lamellae (Fig. 2 A,B).

Qualitative examination of the Goodpasture and Alport antigens. The Goodpasture antigen was present in the kidneys of affected bull terriers and normal non-bull terrier dogs, but fluorescence was weak (Fig. 3). There was variable binding of the antibody Mab A2 to the GCBM, and to the basement membranes of the distal tubules, and there was no binding to Bowman's capsule. There was no difference in the intensity of binding to the kidneys of affected and unaffected dogs (Table 4).

The Alport antigen was also demonstrated in the kidneys of adult affected bull terriers. There was binding of the antibody to the GCBM and basement membrane of the distal tubules, and only minimal fluorescence of the proximal tubules and Bowman's capsule. Again there was no difference in intensity of fluorescence between affected and unaffected dogs. The intensity of fluorescence was greater for the Alport antigen than for the Goodpasture antigen (Table 4).

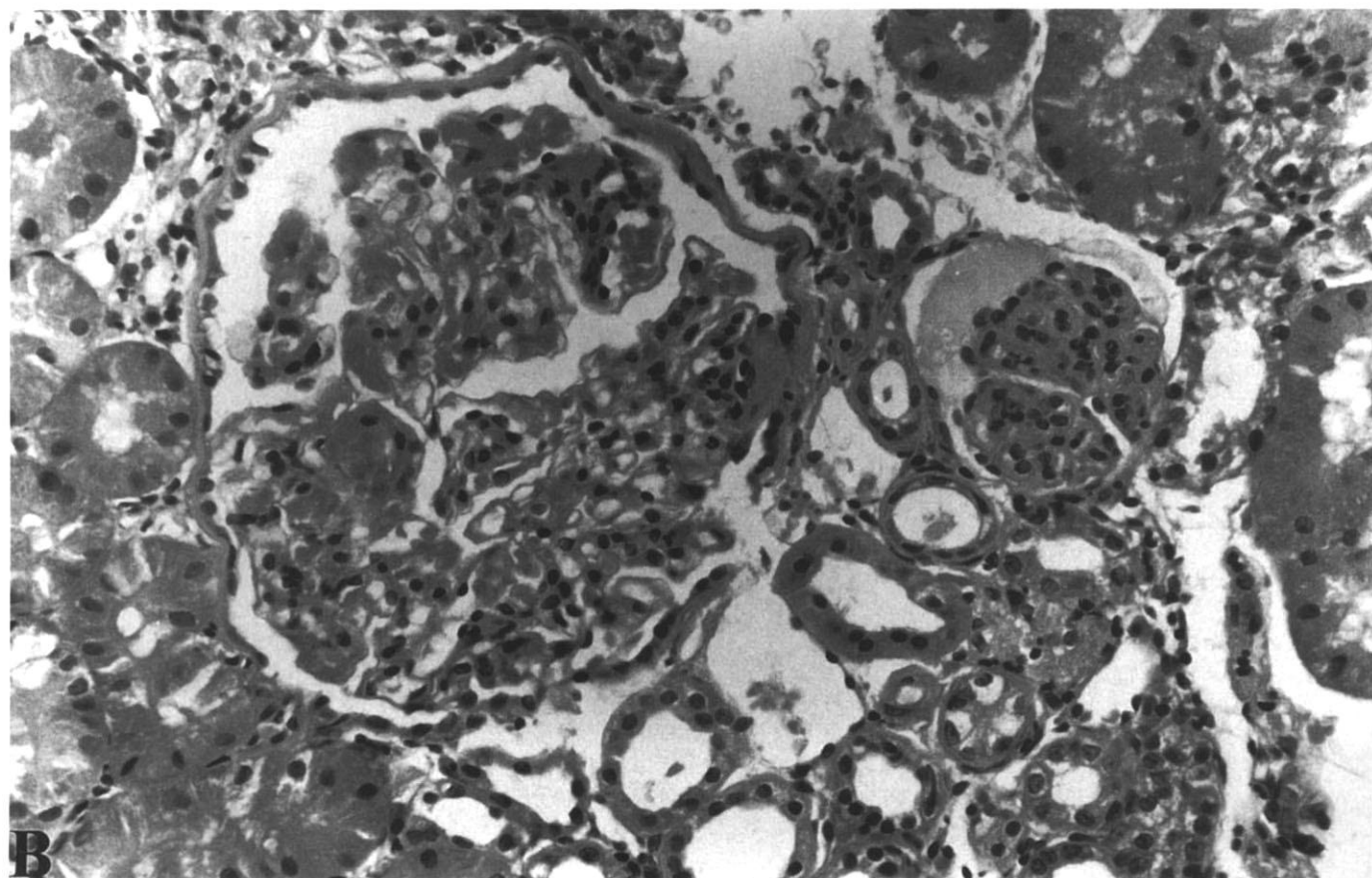
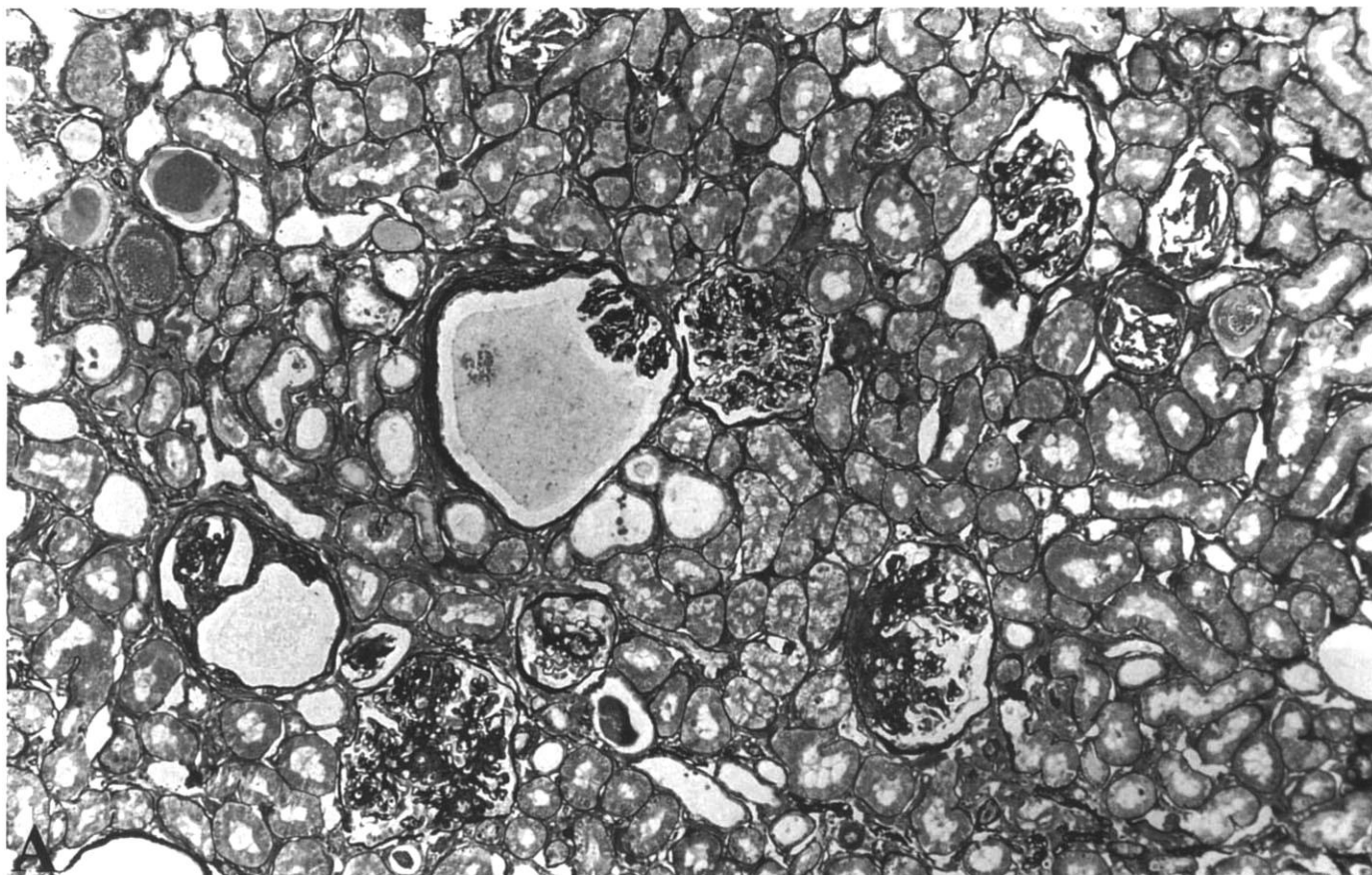
Quantitation of Goodpasture antigen using an ELISA

Goodpasture serum bound to GCBM extracted from both an affected bull terrier and a normal dog and there appeared to be no reduction in the amount of binding in the affected animal (Fig. 4).

Discussion

Bull terrier hereditary nephritis resembles X-linked Alport syndrome in that affected animals have hematuria, progressive renal failure, anterior lenticonus and a lamellated GCBM. However, the disease in bull terriers is distinguished by: its autosomal dominant inheritance [26]; the lack of an association with deafness, even in animals with marked renal impairment; the demonstration of cystic changes in the kidneys [28]; and the presence of both the Goodpasture and Alport antigens in the GCBM.

It appears that most patients with autosomal Alport syndrome have an identical phenotype to patients with X-linked disease. Any distinguishing features have been difficult to determine because very few affected families have been identified. Platelet



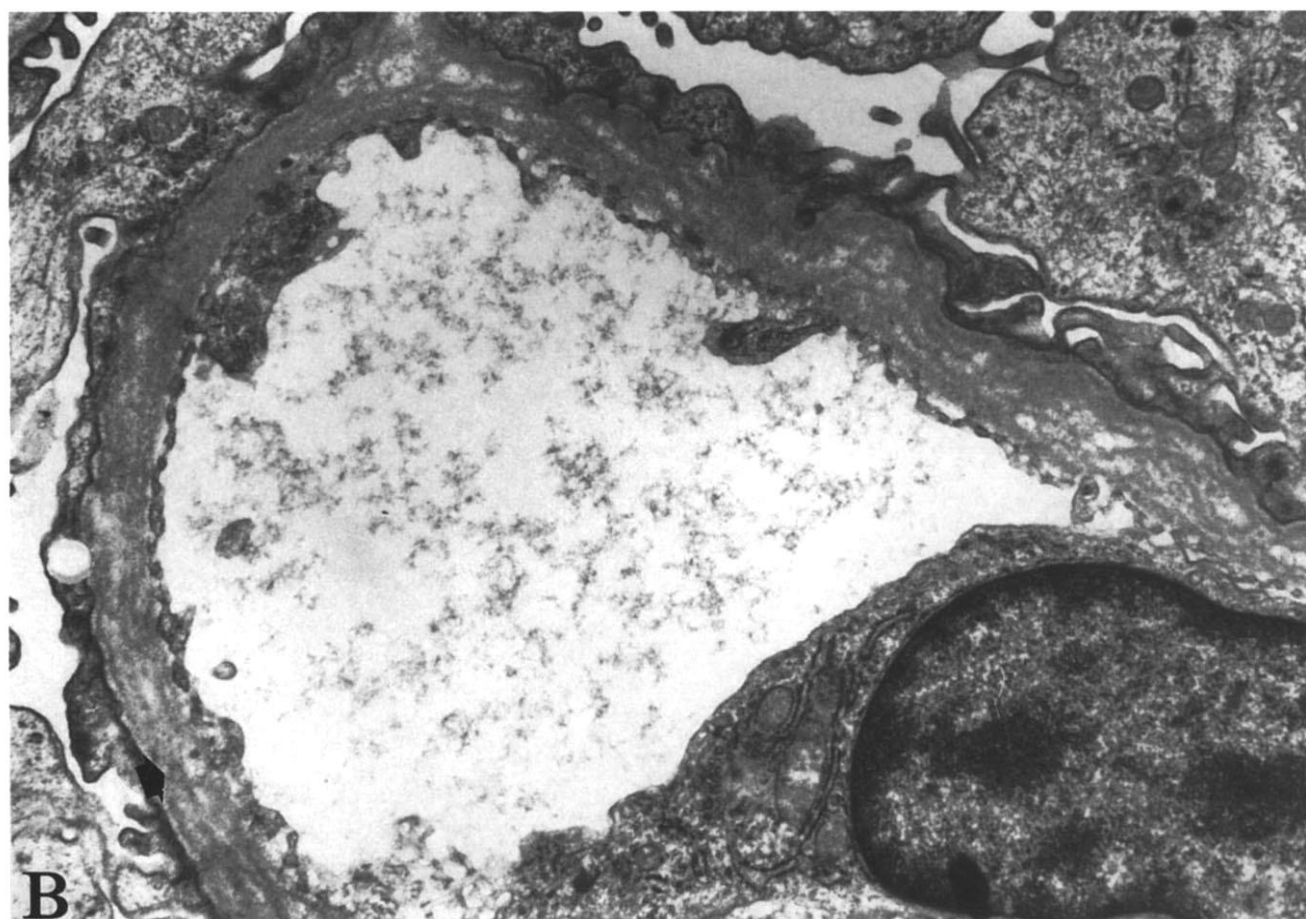
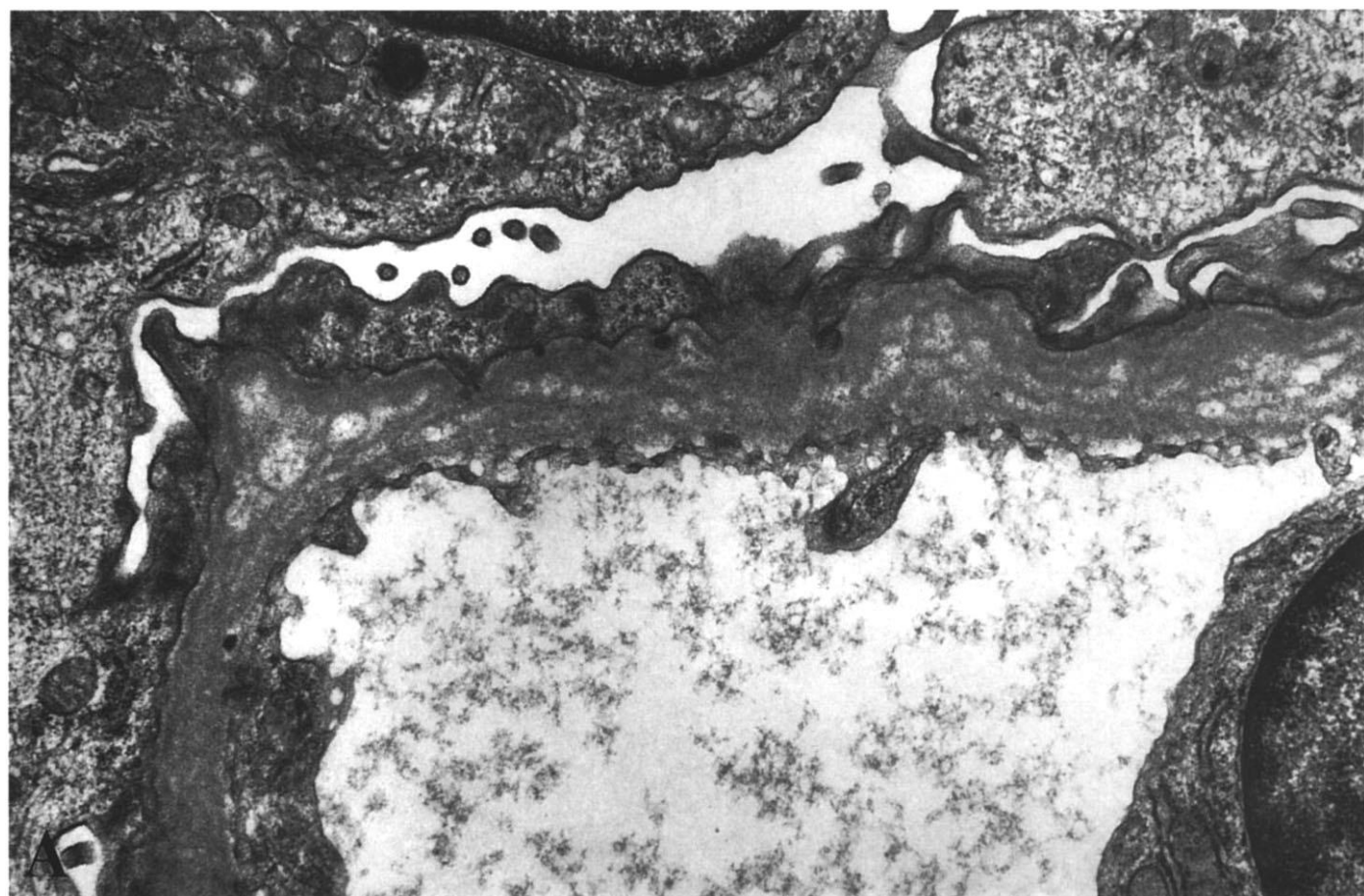


Fig. 2. A. Electron micrographs of glomerular capillary basement membrane (GCBM) from affected adult female bull terrier showing thickening, lamellation and subepithelial projections ($\times 17,500$). **B.** GCBM of daughter of the dog in A showing thickening, lamellation and localized intramembranous electron-dense deposits (arrowed; $\times 17,500$).

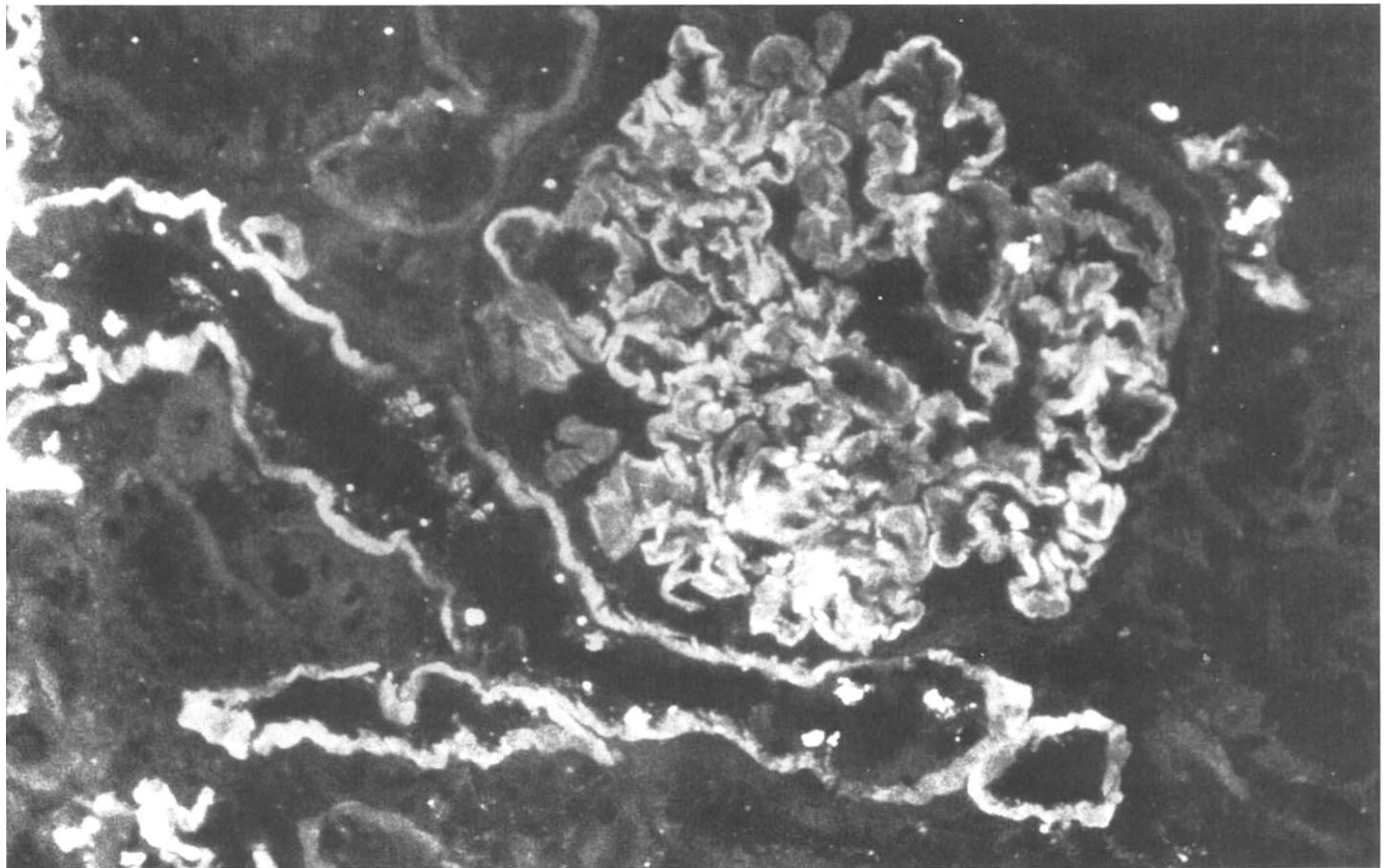


Fig. 3. Kidney section from affected adult bull terrier after incubation with Mab2, specific for Goodpasture antigen, showing linear fluorescence of the glomerular capillary basement membrane (GCBM) and distal tubular basement membrane.

Table 4. Immunofluorescence of basement membranes of kidneys from affected bull terriers and normal dogs

Antibody	Animal	GCBM	Mesangium	Bowman's capsule	TBM
Mab2	affected	3+	3+	0	2+ patchy
	affected	2+	2+	0	2/3+ patchy
	affected	2/3+	0	0	2/3+ patchy
	affected	2/3+	0	0	2+ patchy
	normal	1+ patchy	0	0	1+ patchy
	normal	2+	0	0	2+ patchy
Mab 7	affected	3+	3+	1+	1/3+
	affected	3+	3+	1+	1/3+
	affected	3+	0	1+	1/3+
	affected	3+	0	1+	1/3+
	normal (BT)	3+	0	1+	1/3+
	normal	3+	0	1+	1/3+
	normal	3+	0	1+	1/2+
	normal	2/3+	0	1+	1/2+

Abbreviations are: Mab2, monoclonal antibody specific for Goodpasture antigen; Mab7, monoclonal antibody specific for Alport antigen; BT, bull terrier. The brightest fluorescence with Mab7 was in the distal tubules.

and leukocyte abnormalities sometimes occur in autosomal disease [12–14]. It has been suggested that deafness and anterior lenticonus occur less often [2], but these are not invariable in

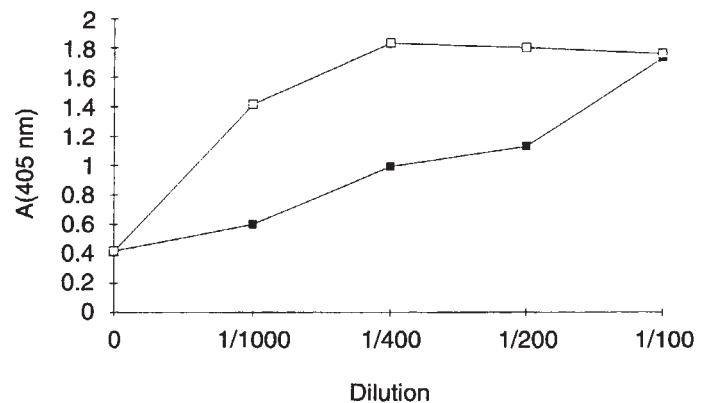


Fig. 4. Binding curves of Goodpasture sera to GCBM from bull terrier with hereditary nephritis (□) and normal dog (■), demonstrating that the alpha 3 chain of type IV collagen is present in at least equal abundance in affected as in normal dogs.

X-linked Alport syndrome [11]. In bull terriers with autosomal Alport syndrome, hereditary deafness occurs, but it is inherited independently of renal disease, and segregates rather with coat color [32]. Anterior lenticonus is present in affected bull terriers, but the retinopathy has not been identified unequivocally because

of the spotted nature of the dog fundus. Platelet size cannot be used to distinguish bull terriers with hereditary nephritis from unaffected dogs. While a small population of larger platelets exists in affected bull terriers, this observation has no clinical predictive value. Large platelets are common in animals with renal failure from any cause, but the blood films that we examined were not from azotemic animals.

Hematuria is a feature of X-linked Alport syndrome that is also found in bull terrier hereditary nephritis, but is not invariably present. Hematuria is much more likely to occur in bull terriers with proteinuria than in those without, but only 41% of the 92 dogs examined with proteinuria had hematuria. In contrast, hematuria is an early finding and usually predates the development of significant proteinuria in human Alport syndrome. Hematuria is also found in animals with Samoyed hereditary glomerulopathy.

The ultrastructural appearance of the GCBM, Bowman's capsule and the tubular basement membranes in bull terrier hereditary nephritis are identical to those seen in X-linked Alport syndrome. Lamellation of the GCBM and intramembranous deposits are seen. In addition, many of the histological features in affected bull terriers such as capillary loop collapse, glomerular sclerosis and fetal glomeruli are also present in Alport kidneys [33]. However, in contrast to Alport syndrome cystic glomerular changes are also prominent in many of the dogs. These do not resemble "polycystic kidneys" in that the kidneys overall are small, firm and finely nodular, and serial renal biopsies taken years apart show no progressive cyst formation.

The abnormal GCBM in male patients with X-linked Alport syndrome is often associated with the absence of the Goodpasture and Alport antigens. The abnormal alpha5(IV) chain presumably affects the stability of the alpha 3(IV) chain with which it normally forms a triple helix. We have confirmed the presence of the Goodpasture antigen in the GCBM of affected bull terriers using both a monoclonal antibody and Goodpasture serum. Previous studies have demonstrated that only one in 10 Goodpasture sera bind to dog GCBM and that there is little of the corresponding antigen in dog kidneys [20]. Nevertheless, Goodpasture serum has been used to distinguish between the GCBM of Samoyed hereditary glomerulopathy and that of unaffected animals. Furthermore, we have shown that there are differences between the distribution of the Goodpasture and Alport antigens in bull terriers and humans: in both unaffected bull terriers and those with hereditary nephritis, there is no Goodpasture antigen and little Alport antigen in Bowman's capsule.

Most bull terriers with hereditary nephritis are related to a single dog and the mutation will be identical in all affected progeny. The abnormal gene is unlikely to correspond to the alpha 5(IV) chain since this is located on the X chromosome, but it could involve one of the genes for another type IV collagen chain. The demonstration of a mutation in autosomal Alport syndrome in the gene for the alpha 3(IV) chain [15] makes this, as well as the alpha 4(IV) chain, likely candidates for the abnormal protein in bull terrier hereditary nephritis, but a mutation in the alpha 3(IV) chain is less likely since the Goodpasture antigen is present.

Acknowledgments

This work was partly supported by the National Health and Medical Research Council of Australia (JS) and an Australian Kidney Foundation

Summer Scholarship (WR). We received invaluable assistance from the Bull Terrier Club of Western Australia, Heather Simpson and the Bull Terrier Club of Victoria, and Mr Keith Newton, a devoted owner of Bull Terriers, of the United Kingdom. The audiometry was performed by Dr Ray Johnstone and Dr Victor Seoh, and the ophthalmological examinations by Dr Deb Colville and Dr Andrew Turner.

Reprint requests to Jennifer Hood, B.Sc., Hon BVMS, Section of Pathology, School of Veterinary Studies, Murdoch University, Murdoch, Western Australia, Australia.

References

- ALPORT AC: Hereditary familial congenital haemorrhagic nephritis. *Brit Med J* 1:504-506, 1927
- FLINTER F: Molecular genetics of Alport's syndrome. *Quart J Med* 86:289-292, 1993
- HINGLAIS N, GRUNFELD J-P, BOIS E: Characteristic ultrastructural lesion of the glomerular basement membrane in progressive hereditary nephritis (Alport's syndrome). *Lab Invest* 27:473-487, 1972
- SPEAR GS, SLUSSER RJ: Alport's syndrome: Emphasizing electron microscopic studies of the glomerulus. *Am J Pathol* 69:213-224, 1972
- MCCOY C, JOHNSTONE HK, STONE WJ, WILSON CB: Variation in glomerular basement membrane antigens in hereditary nephritis. (abstract) *Lab Invest* 34:325A, 1976
- OLSON DL, ANAND SK, LANDING BH, HEUSER E, GRUSHKIN CM, LIEBERMAN E: Diagnosis of hereditary nephritis by failure of glomeruli to bind anti-glomerular basement membrane antibodies. *J Paediatr* 96:697-699, 1980
- BUTKOWSKI RJ, LANGEVELD JPM, WIESLANDER J, HAMILTON J, HUDSON BG: Localisation of the Goodpasture epitope to a novel chain of basement membrane collagen. *J Biol Chem* 262:7874-7877, 1987
- SAUS J, WIESLANDER J, LANGEVELD JPM, QUINONES S, HUDSON BG: Identification of the Goodpasture antigen as the alpha 3(IV) chain of collagen type IV. *J Biol Chem* 263:13374-13380, 1988
- BARKER DF, HOSTIKKA SL, ZHOU J, CHOW LT, OLIPHANT AR, GERKEN SC, GREGORY MC, SKOLNICK MH, ATKIN CL, TRYGGVASON K: Identification of mutations in the COL4A5 collagen gene in Alport syndrome. *Science* 248:1224-1227, 1990
- TRYGGVASON K, ZHOU J, HOSTIKKA SL, SHOWS TB: Molecular genetics of Alport syndrome. *Kidney Int* 43:38-44, 1993
- ATKIN CL, GREGORY MC, BORDER WA: Alport syndrome (Chapt 19), in *Diseases of the Kidney*, edited by SCHRIER RW, GOTTSCHALK CW, Boston, Little, Brown and Co, 1988, pp 617-641
- ECKSTEIN JD, FILIP DJ, WATTS JC: Hereditary thrombocytopenia, deafness and renal disease. *Ann Intern Med* 82:639-645, 1975
- EPSTEIN CJ, SAHUT MA, PIEL CF, GOODMAN JR, BERNFIELD MR, KUSHNER JH, ABLIN AR: Hereditary macrothrombocytopathia, nephritis and deafness. *Am J Med* 52:299-310, 1972
- PETERSON LC, VENKATESARA RAO K, CROSSON JT, WHITE JG: Fechtner syndrome—a variant of Alport's syndrome with leukocyte inclusions and macrothrombocytopenia. *Blood* 65:397-406, 1985
- MOCHIZUKI T, LEMMINCK HH, MARIYAMA M, ANTIGNAC C, GUBLER M-C, PIRSON Y, VERELLEN-DUMOULIN C, CHAN B, SCHRODER CH, SMEETS HJ, REEDERS ST: Identification of mutations in the alpha 3(IV) and alpha 4(IV) collagen genes in autosomal recessive Alport syndrome. *Nature Genet* 8:77-81, 1994
- JANSEN B, TRYPHONAS L, WONG J, THORNER P, MAXIE MG, VALLI VE, BAUMAL R, BASRUR PK: Mode of inheritance of Samoyed hereditary glomerulopathy in humans. *J Lab Clin Med* 107:551-555, 1986
- JANSEN B, VALLI VEO, THORNER P, BAUMAL R, LUMSDEN JH: Samoyed hereditary glomerulopathy (SHG): Serial clinical and laboratory (urine, serum biochemistry and haematology) studies. *Can J Vet Med* 51:387-393, 1987
- JANSEN BS, THORNER PS, SINGH A, PATTERSON JM, LUMSDEN JH, VALLI VE, BAUMAL R, BASRUR PK: Hereditary nephritis in Samoyed dogs. *Am J Pathol* 116:175-178, 1984
- JANSEN B, THORNER P, BAUMAL R, VALLI V, MAXIE MG, SINGH A: Samoyed hereditary glomerulopathy (SHG): Evolution of splitting of glomerular capillary basement membranes. *Am J Pathol* 125:536-545, 1986

20. THORNER P, JANSEN B, BAUMAL R, VALLI VE, GOLDBERGER A: Samoyed hereditary glomerulopathy: immunohistochemical staining of basement membrane of kidney for laminin, collagen type IV, fibronectin and Goodpasture antigen, and correlation with electron microscopy of glomerular capillary basement membranes. *Lab Invest* 56:435–443, 1987
21. THORNER P, BAUMAL R, VALLI VEO, MAHURAN D, MC INNES R, MARRANO P: Abnormalities in the NC1 domain of collagen type IV in GBM in canine hereditary nephritis. *Kidney Int* 35:843–850, 1989
22. BAUMAL R, THORNER P, VALLI VEO, MCINNES R, MARRANO R, JACOBS R, BINNINGTON A, BLOEDOW AG: Renal disease in carrier female dogs with X-linked hereditary nephritis. Implications for female patients with this disease. *Am J Pathol* 139:751–764, 1991
23. VALLI VEO, BAUMAL R, THORNER P, JACOBS R, MARRANO P, DAVIES C, QIZILIBAH B, CLARKE H: Dietary modification reduces splitting of glomerular basement membranes and delays death due to renal failure in canine X-linked hereditary nephritis. *Lab Invest* 65:67–73, 1991
24. ROBINSON WF, SHAW SE, STANLEY B, KABAY M, WASTON ADJ, FRIEND SCE, MITTEN RW: Chronic renal disease in Bull terriers. *Aust Vet J* 66:193–195, 1989
25. NASH AS, McCANDLISH IAP: Chronic renal failure of young Bull terriers. *Vet Record* 118:735, 1986
26. HOOD JC, ROBINSON WF, HUXTABLE CR, BRADLEY JS, SUTHERLAND RJ, THOMAS MAB: Hereditary nephritis in the bull terrier: Evidence for inheritance by an autosomal dominant gene. *Vet Record* 126:456–459, 1990
27. HOOD JC, ROBINSON WF, CLARK WF, SUTHERLAND RJ, JAMES H, THOMAS MAB, HUXTABLE CR: Proteinuria as an indicator of early renal disease in bull terriers with hereditary nephritis. *J Small Animal Practice* 32:241–248, 1991
28. HOOD JC, CRAIG AJ: Hereditary nephritis in a miniature Bull terrier. *Vet Record* 135:138–140, 1994
29. KLEPPEL MM, FAN WW, CHEONG HI, KASHTAN CE, MICHAEL AF: Immunochemical studies of the Alport antigen. *Kidney Int* 41:1629–1637, 1992
30. YOSHIOKA K, MICHAEL AF, VELOSA J, FISH AJ: Detection of a hidden nephritogenic antigen determinants in human renal and non-renal basement membranes. *Am J Pathol* 121:156–165, 1985
31. SPIRO RG: Studies on the renal glomerular basement membrane. Preparation and chemical composition. *J Biol Chem* 242:1915–1922, 1967
32. HAYES HM, WILSON GP, FENNER WR, WYMAN M: Canine congenital deafness: Epidemiologic study of 272 cases. *J Am Animal Hosp Assoc* 17:473–478, 1981
33. RUMPELT HJ, STEINKE A, THOENES W: Alport-type glomerulopathy: Evidence for diminished capillary loop size. *Clin Nephrol* 37:57–64, 1992