



SHORT CONTRIBUTION

Unilateral deafness in a white Bull Terrier diagnosed by BAER assessment

LA AHLSTRÖM^{ab}
WJ WILSON^a
PC MILLS^c

University of Queensland,
St Lucia, Queensland 4072.

ABR	Auditory brainstem response(s)
BAEP	Brainstem auditory evoked potential(s)
BAER	Brainstem auditory evoked response(s)
nHL	Normal hearing level

Aust Vet J 2005;83:742-743

Hereditary deafness is common in many breeds of dogs such as Bull Terriers, Dalmatians, Australian Cattle Dogs and Jack Russell Terriers, and particularly in those with white pigmentation.¹⁻⁴ Dogs that are born with this condition can be bilaterally or unilaterally deaf. A recently published study found that 20% of white Bull Terriers were deaf, the majority (18 %) being unilaterally affected.⁵

While bilateral deafness in a dog may be obvious to its owner, the more prevalent condition of unilateral deafness is much more difficult to recognise.^{2, 6-8} Many unilaterally deaf dogs are able to compensate for their disability, which can result in owners being unaware that their dog has a hearing impairment.⁶

Behavioural testing can be used by veterinarians to attempt to diagnose deafness, but is often unreliable and subjective.^{7,9,10} Importantly, unilateral deafness is often unable to be diagnosed with behavioural testing.^{2, 6, 9}

To diagnose unilateral deafness with confidence, electrodiagnostic testing should be employed.^{6, 9} There are many of these tests available,⁹ but the definitive test is the brainstem auditory evoked response (BAER), also known as the brainstem auditory evoked potential (BAEP), or the auditory brainstem response (ABR).⁶ BAER is the currently preferred term. The BAER test is objective, accurate, relatively non-invasive and allows determination of the degree of deafness and site of impairment.^{7, 9}

This report details the case of a white Bull Terrier that was found to be normal on clinical, behavioural and otoscopic examinations, but was diagnosed with unilateral deafness following BAER testing.

The dog was an entire female Bull Terrier, approximately 4-years-old. Its coat colour was predominantly white, with a brindle patch on the rump and around one eye. The iris colour of both eyes was brown.

The dog was found to be in good health on clinical examination. There was no evidence of ear pain or deafness. The dog responded normally during behavioural assessment. Otoloscopic

^aSchool of Veterinary Science

^bCorresponding author Email: s351024@student.uq.edu.au

^cSchool of Health and Rehabilitation Sciences

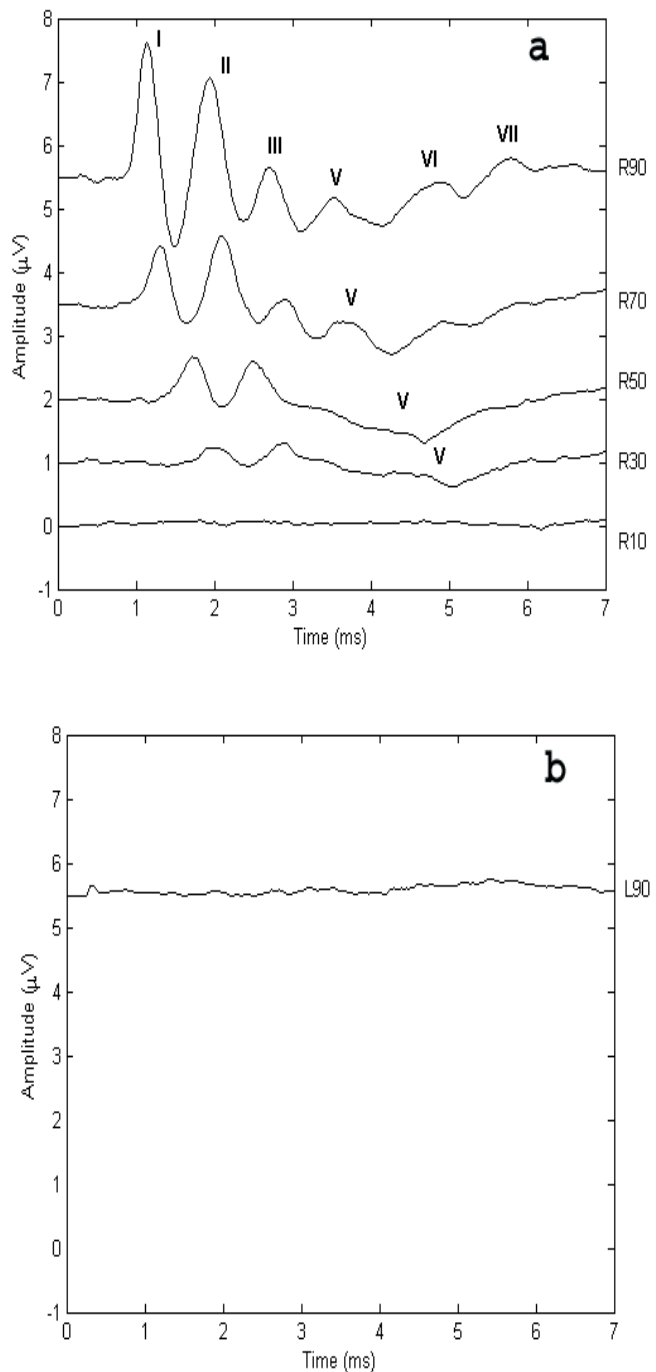


Figure 1. BAEP waveforms generated by stimulating the right ear (a) with 90, 70, 50, 30 and 10 dBnHL stimuli and the left ear (b) with 90 dBnHL stimuli.

examination revealed that both tympanic membranes were intact and ear canals were clean and grossly normal.

A complete BAER threshold assessment was performed to assess the dog's auditory function. Since BAER are not significantly affected by anaesthesia,^{2, 6, 7, 9, 11} the dog was sedated for this 20 min procedure with 30 µg/kg medetomidine hydrochloride (Domitor®), administered subcutaneously. It should be noted that the BAER testing protocol employed in this instance was a much more rigorous assessment than is necessary to screen for inherited deafness, which may only require a test stimulus of a

single dB level (for example 100 dB), resulting in a much shorter procedure (less than 10 min) which can often be performed without sedation.

The BAER test assesses hearing by detecting the electrical activity in the VIIIth cranial nerve and auditory brainstem that is generated in response to an auditory stimulus.^{9,11} This electrical activity is displayed as a response waveform consisting of a series of peaks which represent the neuroelectrical activity at various points along the auditory pathway. Interpretation of a BAER recording is based on the presence of the expected peaks, as well as their latency and amplitude.⁹

In the current study, the dog's BAER were obtained using a personal computer running Biologic Systems Incorporated Evoked Potentials Software (EP version 5.39, model 317). To detect each BAER, stainless steel needle electrodes were placed subcutaneously on the dog's vertex (non-inverting), and rostral to the tragus of the test ear (inverting) and the non-test ear (ground). To elicit each BAER, TDH-39P headphones were placed over the dog's ears and the test ear was stimulated with alternating acoustic clicks while the non-test ear was masked with white noise. The clicks were driven by 0.1 ms square wave electrical impulses that produced broadband acoustic clicks containing frequencies between approximately 500 Hz and 4000 Hz, with the peak energy occurring at approximately 3000 Hz. Stimulus intensities were set at 90, 70, 50, 30 and 10 dBnHL and the BAER response threshold was defined as the lowest stimulus level at which a repeatable waveform could be obtained.

The signal averaged BAER generated in response to the stimulation of the dog's right ear were normal with decreased amplitude and prolonged latency as stimulus intensity decreased (see Figure 1a). This is consistent with normal auditory function to the level of mid brainstem from this ear.^{9,11} When the loudest test stimuli (90 dBnHL) were delivered to the left ear however, the response waveform appeared as a flat line, showing none of the expected peaks (see Figure 1b). This absence of a response is indicative of

severe to profound loss of auditory function in the left ear.

It is important to realise that canine unilateral deafness may not be apparent to the owner or veterinarian. This case illustrates the potential for unilateral deafness to remain undetected in affected dogs, and the importance of BAER testing in achieving a diagnosis. The Bull Terrier in this case appeared normal after clinical, otoscopic and behavioural examinations, and it was not until BAER assessment was performed that severe to profound loss of auditory function in its left ear was detected. Owners of dogs at risk of deafness should be informed about this possibility and made aware of the testing methodologies available. Although behavioural assessment is not a reliable diagnostic test for the detection of unilateral deafness,^{2,6,7,9} BAER testing offers veterinarians and owners a reliable and relatively non-invasive technique to assess hearing.

The authors would like to thank Dermcare-Vet Pty Ltd for their generous support.

References

1. Strain GM, Kearney MT, Gignac IJ et al. Brainstem auditory-evoked potential assessment of congenital deafness in Dalmatians: Associations with phenotypic markers. *J Vet Intern Med* 1992;6:175-182.
2. Strain GM. Aetiology, prevalence and diagnosis of deafness in dogs and cats. *Br Vet J* 1996;152:17-36.
3. Cargill EJ, Famula TR, Strain GM, Murphy KE. Heritability and segregation analysis of deafness in U.S. Dalmatians. *Genetics* 2004;166:1385-1393.
4. Famula TR, Oberbauer AM, Sousa CA. A threshold model analysis of deafness in Dalmatians. *Mamm Genome* 1996;7:650-653.
5. Strain GM. Deafness prevalence and pigmentation and gender associations in dog breeds at risk. *Vet J* 2004;167:23-32.
6. Strain GM. Congenital deafness and its recognition. *Vet Clin N Am Small Anim Pract* 1999;29:895-907.
7. Cox C. Investigation of hearing loss in dogs. *In Pract* 2002;24:494-501.
8. Merchant SR. Ototoxicity. *Vet Clin N Am Small Anim Pract* 1994;24:971-980.
9. Sims MH. Electrodiagnostic evaluation of auditory function. *Vet Clin N Am Small Anim Pract* 1988;18:913-944.
10. Strain GM. Brainstem auditory evoked potentials in veterinary medicine. *Br Vet J* 1992;148:275-278.
11. Sims MH, Moore RE. Auditory-evoked response in the clinically normal dog: Early latency components. *Am J Vet Res* 1984;45:2019-2027.

(Accepted for publication 22 June 2005)

BOOK REVIEW

Veterinary Endoscopy for the Small Animal Practitioner. McCarthy TC. Saunders/Elsevier Australia, Marrickville, 2005, 606 pages. Price A\$247.50. ISBN 0 7216 3653 5.

This book is a thorough review of the techniques and uses of endoscopy in small animal practice. It begins with an outline of the equipment and its adaptability to various uses, covering both rigid and flexible scopes. The text then goes through the various systems and how endoscopy can be applied. Examination, biopsy and manipulative procedures are covered, with each chapter detailing a different body system. The book is edited by Tim McCarthy and various chapters are contributed by well known experts in their fields. Although not heavily referenced, this text is very readable and easy to understand.

Of particular value are extensive endoscopic photographs showing normal and abnormal anatomy. Each photograph is accompanied by a usefully labelled diagram. Understanding the normal and detecting the abnormal is a challenge for veterinarians new to endoscopy, and this text provides a good reference on the normal and pathological appearance of the various areas.

I found the chapters on thoracoscopy and laparoscopy to be very constructive in providing advice on getting started in these fields. The chapters on the respiratory and gastrointestinal systems are thorough and interesting. There is an informative chapter on arthroscopy, although if this is the main interest other texts are more useful.

Over all, this is a very good book for practitioners interested in this rapidly developing field, and will help to maximise the usefulness of the expensive equipment by encouraging a wider range of applications.

J Culvenor

Dr John Culvenor is a Specialist Small Animal Surgeon in practice in Sydney.